

CLINICAL REVIEW

Thunderclap headache

Anne Ducros *neurologist*¹, Marie-Germaine Bousser *professor of neurology*²¹Emergency Headache Centre, Head and Neck Clinic, Lariboisière Hospital, Assistance Publique Hôpitaux de Paris, 75010 Paris, France; ²Neurology Department, Head and Neck Clinic, Lariboisière Hospital

Headache affects about 90% of the general population. The most common causes are migraine and episodic tension-type headache. A small proportion of patients present acutely to a primary care doctor, and the main objective is to identify those who require urgent investigations.

The term thunderclap headache is used to describe a severe headache of instantaneous onset—one minute at the most.¹ Estimated incidence is about 43 per 100 000 adults per year in the developed world.² In our emergency headache centre, out of a total of 8000 patients each year, about 120 present with thunderclap headache. Any thunderclap headache, even in a patient with a history of recurrent headache, such as migraine, must be considered as secondary to a variety of causes, the foremost of which is subarachnoid haemorrhage.³⁻⁴ Making a diagnosis can be challenging. Even when brain computed tomography (CT) and lumbar puncture results are normal, the underlying cause can be serious—for example, cervical artery dissection, cerebral venous thrombosis, and reversible cerebral vasoconstriction syndrome (RCVS).⁴⁻⁵

This review aims to describe the various causes of thunderclap headache and the role of investigations when CT and lumbar puncture investigations are normal.

What is a thunderclap headache?

This clinical form of headache is defined by its mode of onset and severity.⁶⁻⁷ A detailed history is needed to recognise a thunderclap headache. First ask the patient precisely how long the headache took to peak and then what the maximum severity was on an 11 point scale (0 no pain; 1-3 mild pain; 4-6 moderate pain; 7-9 severe pain; 10 worst pain ever). A headache that reaches 7 or more within less than one minute is a thunderclap headache. Headache that is present on awakening cannot by definition be called a thunderclap headache, although it may be one. Thunderclap headaches may last from minutes to several days. The location and type of pain are not specific. Thunderclap headaches may be single or recur over a few days. They may start spontaneously or during performance of the Valsalva manoeuvre, exertion, sexual activity, emotional stress, bathing, or showering. General practitioners should urgently refer a patient with thunderclap headache to the emergency department

and, whenever possible, to a hospital with a neurology department.

How should a patient with thunderclap headache be assessed?

Circumstances preceding the onset, including exposure to vasoactive drugs, may provide clues to some diagnoses (box 1). Associated neurological symptoms and any abnormality in the neurological or physical examination increase the need for rapid evaluation. In particular, always check eyelids, pupils, visual field, and cerebellar function for subtle signs (box 2). The absence of any associated symptoms and a strictly normal examination do not exclude a serious cause—urgent diagnostic work-up is still needed.

What are the most common causes?

Subarachnoid haemorrhage

Systematic reviews and prospective observational studies have shown that about 70% of subarachnoid haemorrhages present primarily with headache, which has a thunderclap pattern in 50%.⁸⁻¹¹ Subarachnoid haemorrhage is found in 11-25% of patients who present with thunderclap headache.²⁻⁹ Any thunderclap headache must raise suspicion of an underlying subarachnoid haemorrhage, even in an alert pain-free patient with a supple neck at the time of presentation.¹⁰ The shortest duration of headache caused by a subarachnoid haemorrhage is unknown. Subarachnoid haemorrhage is initially misdiagnosed in about one of three patients, especially those who have a normal Glasgow coma scale score and present with isolated headache.¹⁰

First perform unenhanced brain CT, followed by lumbar puncture if the tomogram is normal,³⁻¹¹ because a normal result does not exclude subarachnoid haemorrhage. CT results are normal in 2% of cases within 12 hours after headache onset, 10% after one day, and 50% after five days.¹⁰ Systematic reviews show that magnetic resonance imaging (MRI) is as sensitive as CT for the detection of subarachnoid blood within the first few hours and becomes more sensitive after the first day.¹¹ However, like CT, the sensitivity of early MRI is not 100%.

Summary points

Thunderclap headache is a severe headache that peaks within 60 seconds of onset

Neurovascular disorders often present with thunderclap headache

Infectious disorders, intracranial hypertension, and hypotension syndromes occasionally present with thunderclap headache

Subarachnoid haemorrhage is the most common cause; diagnosis is based on plain brain computed tomography (CT) and, if normal, on lumbar puncture

Suspect reversible cerebral vasoconstriction syndrome when thunderclap headaches recur over a few days

Cervical artery dissection, cerebral venous thrombosis, reversible cerebral vasoconstriction syndrome, and pituitary apoplexy may present with isolated thunderclap headache and normal physical examination, CT, and cerebrospinal fluid

When CT and cerebrospinal fluid are normal, other investigations are needed, including cervical and cerebral vascular imaging and brain magnetic resonance imaging

Methods box

We identified references for this review by searching PubMed up to July 2012 with the terms “thunderclap headache”, “acute headache”, “sudden headache”, “subarachnoid haemorrhage”, and “reversible cerebral vasoconstriction”. We also searched the reference lists of the identified articles and our own files. Only papers published in English and French, or with an English abstract, were reviewed. The final reference list was generated on the basis of relevance to the broad scope of this review.

Box 1 Circumstances preceding thunderclap headache that point to possible causes

Mild trauma: Cervical arterial dissection, intracranial hypotension

Intake of vasoactive substances: Illicit drugs (cannabis, cocaine, ecstasy, amphetamines, lysergide); antidepressants (selective serotonin reuptake inhibitors, mixed adrenaline (epinephrine) and serotonin reuptake inhibitors); α sympathomimetics (nasal decongestants, noradrenaline (norepinephrine)); migraine drugs (triptans and ergot alkaloid derivatives): reversible cerebral vasoconstriction syndrome (RCVS)

Dural puncture: Intracranial hypotension

Fever: Infectious disorders

Postpartum: RCVS, cerebral venous thrombosis, eclampsia

Ear, nose, and throat symptoms: Complicated sinusitis

Box 2 Other symptoms and signs that can give a clue to the diagnosis

Neck stiffness: Subarachnoid haemorrhage or meningitis

Transient loss of consciousness: Subarachnoid haemorrhage (around 50% of cases), colloid cyst of the third ventricle

Epileptic seizure: Subarachnoid haemorrhage, other stroke, cerebral venous thrombosis, posterior reversible encephalopathy syndrome (PRES), reversible cerebral vasoconstriction syndrome (RCVS)

Focal neurological symptoms: Subarachnoid haemorrhage, other stroke, cerebral venous thrombosis, PRES, RCVS

Horner's sign or pulsatile tinnitus or tongue palsy: Dissection of the homolateral internal carotid artery

Unilateral mydriasis with or without other signs of third cranial nerve paralysis: Aneurysm compressing the third nerve

Patients avoid lying flat: Subarachnoid haemorrhage, intracranial hypertension syndrome, cerebral venous thrombosis, acute sinusitis

Patients avoid standing up: Intracranial hypotension, cerebellar stroke

Papilloedema: Intracranial hypertension

Arterial hypertension: Subarachnoid haemorrhage, eclampsia, PRES, RCVS

Electrocardiographic abnormalities: Subarachnoid haemorrhage, myocardial infarction with ectopic pain

Asymmetrical blood pressure at upper limbs: Aortic arch dissection

A lumbar puncture is therefore needed in all cases of thunderclap headache after normal brain imaging.¹⁰ If the cerebrospinal fluid (CSF) is bloodstained, it should immediately be centrifuged; yellow coloration (xanthochromia) of the supernatant indicates subarachnoid haemorrhage. This can be confirmed by spectrophotometry, which will show the presence of bilirubin formed *in vivo*. The sensitivity of spectrophotometry for bilirubin is close to 100% when lumbar puncture is performed 12 hours to two weeks after subarachnoid haemorrhage.¹¹

In positive cases, search for a ruptured aneurysm using cerebral angiography. Non-traumatic subarachnoid haemorrhages are caused by a ruptured aneurysm in 85% of cases, whereas 10% are idiopathic perimesencephalic subarachnoid haemorrhages.¹¹ The remaining 5% are caused by rare conditions including intracranial arterial dissection, brain and spinal vascular

malformations and tumours, angitis, cerebral venous thrombosis,¹¹ and RCVS.¹²

Reversible cerebral vasoconstriction syndrome

In two prospective studies of patients with sudden onset headache investigated by plain brain CT and lumbar puncture if needed, 11-25% of cases had subarachnoid haemorrhage, 10-12% had other serious disorders (including strokes, tumours, and meningitis), and the remainder had “no underlying cause” and a good outcome on follow-up.²⁻⁹ These studies led to the concept of “benign thunderclap headache” and to the suggestion that cerebral angiography was not necessary after normal results on CT and lumbar puncture.⁹

Systematic vessel imaging led to the recognition of RCVS as a common cause of thunderclap headache.⁵ A systematic review, based on three large observational studies (two prospective and one retrospective) and numerous smaller case series and reports, showed that RCVS presents as isolated headaches in about 75% of cases.¹³ On the basis of this review and our experience at the emergency headache centre, we believe that RCVS accounts for most “benign thunderclap headaches.”

RCVS is characterised by severe headaches, with or without focal deficits and seizures, and diffuse segmental cerebral arterial vasoconstriction that resolves within three months.¹²⁻¹⁴ Half of cases occur during the postpartum period or after exposure to serotonergic agents, adrenergic substances, or cannabis.^{5 14 15} Most patients have multiple thunderclap headaches that recur every day or so for a few days to four weeks.^{5 13} The pain lasts from five minutes to a few hours. Sexual activity, emotion, exertion, coughing, straining, urination, bathing, and showering are common triggers. A prospective series showed that 60% of patients with isolated sexual headaches had RCVS.¹⁶

In RCVS presenting with isolated headaches, the results of plain brain CT are usually normal and cerebrospinal fluid is either normal or “near normal,” with a mild increase in blood cell counts and protein concentrations.⁵ RCVS is not always benign. Overall, one in four patients has a convexity subarachnoid haemorrhage—a non-aneurysmal, usually mild, subarachnoid haemorrhage in the sulcal spaces of the cerebral hemispheres, near the convexity.¹³ Haemorrhagic and ischaemic stroke can occur, sometimes after a few days of isolated headaches in patients with initial normal brain imaging.^{12 14} Diagnostic criteria for RCVS have been proposed (box 3).¹³ Diagnosis requires the demonstration of diffuse arterial beading by cerebral angiography, usually magnetic resonance angiography (MRA) or CT angiography (CTA), even though these tests are less sensitive than catheter angiography (figure 4). MRA, CTA, and even catheter angiography may be normal up to six or seven days after headache onset in patients who are ultimately shown to have RCVS on repeat angiography.¹²

There is no evidence based treatment for RCVS. Patients should rest, with the duration and type of rest depending on initial severity. Some patients need bed rest in hospital for two weeks; in others, rest at home (avoiding exertion and sex but without bed rest) for a few days to two weeks is sufficient. All vasoactive substances should be removed and avoided even after vasoconstriction resolves (box 1).¹³ Nimodipine—a smooth muscle relaxant that mainly affects cerebral arteries—is mostly used, despite scarce evidence of efficacy. Outcome is usually good, although a few patients are left with permanent deficits from strokes.^{12 14} A few lethal cases—mostly postpartum—have been reported.¹⁵

What are the less common causes of thunderclap headache?

Causes detected by plain CT or lumbar puncture

Two large prospective studies found that other intracranial haemorrhages, easily seen on plain CT, accounted for 5-10% of cases of thunderclap headache (box 4).^{2 9} Rarely, thunderclap headache is caused by ischaemic stroke, which can be diagnosed on plain CT, although diffusion weighted MRI is better.¹⁷ Hydrocephalus and brain tumours such as colloid cysts of the third ventricle occasionally present as repeated thunderclap headaches with nausea and vomiting, because of acute intracranial hypertension provoked by movements, coughing,

or straining.⁴ Thunderclap headache may be followed by coma due to herniation, and the diagnosis can usually be made on plain CT. Acute sinusitis can also cause thunderclap headache but must be regarded as a diagnosis of exclusion.¹⁸

Bacterial or viral meningitis accounts for 2% of cases of thunderclap headache.⁹ Fever and neck stiffness may be lacking. Meningitis can be identified only by analysis of cerebrospinal fluid.¹⁹ Urgent antibiotic or antiviral treatment is needed.

Causes that can be missed by plain CT and lumbar puncture

A systematic review of observational studies and case series showed that some causes of thunderclap headache cannot be ruled out clinically and can present with normal CT and cerebrospinal fluid results (box 4).⁴ Because specific treatments can reduce the risk of complications, early diagnosis in patients with isolated headache is crucial.

About 8% of all patients with cervical artery dissection present with pain as the only symptom; the pain has a thunderclap pattern in 20% of these patients.²⁰ Diagnosis requires imaging of the cervical and intracranial arteries by CTA or an MRI protocol, particularly cervical fat suppressed T1 weighted sequences, to visualise the mural haematoma. Antithrombotic agents are used to prevent ischaemic events.

Thunderclap headache is the presenting and major clinical feature in 2-16% of patients with cerebral venous thrombosis.²¹⁻²³ Diagnosis is based on visualisation of the clot on brain MRI (hypersignal on T1 and T2 weighted sequences and hyposignal on echo planar T2* or susceptibility weighted imaging) associated with a missing sinus on CT or magnetic resonance venography. Treatment is based on heparin.

Posterior reversible leucoencephalopathy syndrome (PRES)—an acute neurological syndrome—may present with thunderclap headache, usually rapidly followed by confusion, seizures, and visual symptoms. Extreme hypertension is common but not constant. PRES is often associated with RCVS.^{12 14 24} MRI shows reversible vasogenic brain oedema (hyperintensity on T2 weighted sequences) and MRA or CTA can detect associated vasospasms.²⁴ The most common causes of PRES are hypertensive encephalopathy and eclampsia.

Thunderclap headache is the presenting feature in 15% of people with intracranial hypotension.²⁵ After its sudden onset, the headache becomes a typical positional headache that occurs or worsens while sitting or standing and is relieved by lying down. Most cases occur after dural puncture. Spontaneous intracranial hypotension is more difficult to diagnose. CT is often normal. Opening pressure may be low or unobtainable on lumbar puncture, which is best avoided. Brain MRI with gadolinium is the best diagnostic test but may be normal in the first days. Epidural blood patch is the treatment of choice.

Finally, case reports suggest that thunderclap headache may also be caused by pituitary apoplexy²⁶ and, rarely, spontaneous retroclival haematoma,²⁷ myocardial infarction,²⁸ and aortic dissection.²⁹ We have also seen a few cases of thunderclap headache in temporal arteritis.

Which investigations are needed?

Plain head CT and, if CT is normal, lumbar puncture are needed.^{10 30 31} Despite strong advice from health authorities, lumbar puncture is still often omitted.³² Because patients with thunderclap headache may have a mass lesion, brain imaging is mandatory before performing lumbar puncture. If the CSF is clear, it is useful to measure the opening pressure because a

Box 3 Proposed diagnostic criteria for reversible cerebral vasoconstriction syndrome^{6 13 14}

- Acute and severe headache (often thunderclap), with or without focal deficits or seizures
- Uniphasic course without new clinical symptoms more than one month after clinical onset
- Segmental constriction of cerebral arteries on indirect (magnetic resonance or computed tomography) angiography or direct catheter angiography
- No evidence of aneurysmal subarachnoid haemorrhage
- Normal or near normal cerebrospinal fluid results (protein <1 g/L, white blood cells <15×10⁶/L, normal glucose)
- Complete or marked normalisation of arteries on follow-up indirect or direct angiography performed within 12 weeks of clinical onset

Box 4 Secondary causes of thunderclap headache*Causes usually detected by plain brain computed tomography (CT)*

- Subarachnoid haemorrhage (95% during the 24 hours after bleeding)
- Intracerebral haemorrhage
- Intraventricular haemorrhage
- Acute subdural haemorrhage
- Brain infarct (after three hours)
- Tumour (third ventricle colloid cyst, posterior fossa tumour)
- Hydrocephalus (aqueductal stenosis, Chiari type 1 malformation)
- Acute sinusitis (exclusion diagnosis)

Causes detected by lumbar puncture after normal brain CT

- Subarachnoid haemorrhage
- Meningitis (bacterial or viral)

Causes that may present with normal CT and normal or near normal cerebrospinal fluid

- Dissection of cervical arteries (extracranial, intracranial, carotid, or vertebral)
- Symptomatic aneurysm with mass effect (painful third nerve palsy)
- Reversible cerebral vasoconstriction syndrome
- Posterior reversible encephalopathy syndrome
- Cerebral venous thrombosis (opening pressure may be high)
- Pituitary apoplexy
- Intracranial hypotension (opening pressure is low)
- Brain infarct in patients in whom CT was performed within three hours of onset
- Temporal arteritis
- Myocardial ischaemia
- Aortic dissection

high pressure may point to cerebral venous thrombosis,²¹ and a low pressure to intracranial hypotension. Sufficient fluid has to be collected for white and red blood cell counts, Gram staining, protein and glucose concentrations, visual inspection for xanthochromia, and spectrophotometry.

Some authors recommend waiting 12 hours after headache onset to perform lumbar puncture, so that spectrophotometry can be used to differentiate traumatic taps from subarachnoid haemorrhages.¹¹ Such a delay may be logistically difficult. It exposes patients with meningitis to the risk associated with delayed treatment and those with a ruptured aneurysm to that of early rebleeding, which was seen in just under 14% of cases in the first hours after the initial haemorrhage in a prospective observational study.³³ We therefore do not delay lumbar puncture.

There is still debate about the need for further investigations in patients who have thunderclap headache with normal CT and lumbar puncture results.^{30 31} We and others always perform CTA or MRA.^{4 13 31} Indeed, in subarachnoid haemorrhage, angiography is needed to detect a ruptured aneurysm. If CT is normal, and CSF is normal, near normal (mild increase in cell counts), or possibly bloodstained due to trauma, cervical and cerebral angiography should be performed to look for alternative diagnoses (box 4). Systematic angiography in such cases can

identify incidental unruptured aneurysm, which is present in 2% of the adult population.¹¹ A multidisciplinary neurovascular team can help decide whether the aneurysm requires treatment. Finally, in thunderclap headache with normal CT, normal CSF, and normal CTA or MRA, brain MRI may show cortical cerebral venous thrombosis, pituitary apoplexy, PRES, or intracranial hypotension (box 4).

Large prospective studies of patients presenting with thunderclap headache are needed to establish the incidence of underlying causes and to evaluate the diagnostic yield of angiography and brain MRI after normal CT and lumbar puncture. However, the wide availability of CTA and MRA means that imaging of the cervical and cerebral vessels is now much easier and more acceptable to patients.

When is four vessel cerebral angiography still necessary?

Conventional angiography is indicated in cases of subarachnoid haemorrhage when non-diagnostic CTA or MRA fails to detect an aneurysm.^{3 11} Conventional angiography may be useful in some patients with thunderclap headaches and non-diagnostic MRI, MRA, and CTA, if headache persists or worsens, or if

other symptoms appear, to search for occult intracranial arterial dissection, cerebral vasoconstriction syndrome, or vasculitis.

What about primary headache disorders as a cause of thunderclap headache?

Doctors should always look for an underlying cause of thunderclap headache. It can be dangerous to diagnose a primary headache disorder when onset is abrupt or related to cough, exertion, or sexual activity. Rarely, a patient presenting with a first episode of cluster headache might be investigated for recurrent unilateral thunderclap headache, because cluster pain is severe and can peak in one minute. Investigate patients without a history of a similar headache to exclude a secondary cause, especially a carotid dissection. Thereafter, correct diagnosis of cluster headache relies on clinical re-assessment (box 5).⁶

According to the International Classification of Headache Disorders, diagnosis of a primary headache disorder requires the exclusion of a secondary cause.⁶ “Primary thunderclap headache” was introduced as a distinct entity in the second version of this classification.⁶ However, some doubt whether primary thunderclap headache really exists. We think that all thunderclap headaches are secondary, and that the correct diagnosis can be missed when investigations are performed too early or too late, are incomplete, or lack sensitivity. For example, some cases of RCVS need a repeat CTA or MRA three weeks after headache onset to be detected and others need invasive conventional angiography. Therefore, if the results of all non-invasive investigations are normal and the patient is recurrence-free after a few weeks of follow-up, we use the term “thunderclap headache of undefined origin.”¹³

Contributors: AD drafted the manuscript and is guarantor. M-GB and AD revised the manuscript.

Competing interests: All authors have completed the ICMJE uniform disclosure form at www.icmje.org/coi_disclosure.pdf (available on request from the corresponding author) and declare: no support from any organisation for the submitted work; AD has received payment for board membership from Novartis, lecture fees from Almirall, AstraZeneca, GlaxoSmithKline, Merck, and Pfizer, and has received support for travel, accommodation, and meeting expenses from Almirall and Pfizer; M-GB has received support for travel, accommodation, and meeting expenses from Sanofi, Servier, and Moleac; in addition, AD is associate editor of *Cephalalgia*.

Provenance and peer review: Commissioned; externally peer reviewed.

1 Day JW, Raskin NH. Thunderclap headache: symptom of unruptured cerebral aneurysm. *Lancet* 1986;2:1247-8.

- 2 Landtöblom AM, Fridriksson S, Boivie J, Hillman J, Johansson G, Johansson I. Sudden onset headache: a prospective study of features, incidence and causes. *Cephalalgia* 2002;22:354-60.
- 3 Al-Shahi R, White PM, Davenport RJ, Lindsay KW. Subarachnoid haemorrhage. *BMJ* 2006;333:235-40.
- 4 Schwedt TJ, Matharu MS, Dodick DW. Thunderclap headache. *Lancet Neurol* 2006;5:621-31.
- 5 Ducros A, Boukobza M, Porcher R, Sarov M, Valade D, Bousser MG. The clinical and radiological spectrum of reversible cerebral vasoconstriction syndrome. A prospective series of 67 patients. *Brain* 2007;130:3091-101.
- 6 The international classification of headache disorders. *Cephalalgia* 2004;24:1-160.
- 7 Dodick DW. Thunderclap headache. *J Neurol Neurosurg Psychiatry* 2002;72:6-11.
- 8 Linn FH, Rinkel GJ, Algra A, van Gijn J. Headache characteristics in subarachnoid haemorrhage and benign thunderclap headache. *J Neurol Neurosurg Psychiatry* 1998;65:791-3.
- 9 Linn FH, Wijdevicks EF, van der Graaf Y, Weerdesteyn-van Vliet FA, Bartelds AI, van Gijn J. Prospective study of sentinel headache in aneurysmal subarachnoid haemorrhage. *Lancet* 1994;344:590-3.
- 10 Edlow JA, Caplan LR. Avoiding pitfalls in the diagnosis of subarachnoid hemorrhage. *N Engl J Med* 2000;342:29-36.
- 11 van Gijn J, Kerr RS, Rinkel GJ. Subarachnoid haemorrhage. *Lancet* 2007;369:306-18.
- 12 Ducros A, Fiedler U, Porcher R, Boukobza M, Stapf C, Bousser MG. Hemorrhagic manifestations of reversible cerebral vasoconstriction syndrome. Frequency, features, and risk factors. *Stroke* 2010;41:2505-11.
- 13 Ducros A. Reversible cerebral vasoconstriction syndrome. *Lancet Neurol* 2012;11:906-17.
- 14 Singhal AB, Hajj-Ali RA, Topcuoglu MA, Fok J, Bena J, Yang D, et al. Reversible cerebral vasoconstriction syndromes: analysis of 139 cases. *Arch Neurol* 2011;68:1005-12.
- 15 Fugate JE, Ameriso SF, Ortiz G, Schottlaender LV, Wijdevicks EF, Flemming KD, et al. Variable presentations of postpartum angiopathy. *Stroke* 2012;43:670-6.
- 16 Yeh YC, Fuh JL, Chen SP, Wang SJ. Clinical features, imaging findings and outcomes of headache associated with sexual activity. *Cephalalgia* 2010;30:1329-35.
- 17 Lopes Azevedo L, Breder R, de ASDP, de Freitas GR. Ischemic stroke presenting as thunderclap headache: report of two cases and review of the literature. *Eur Neurol* 2011;66:133-5.
- 18 McGeeney BE, Barest G, Grillone G. Thunderclap headache from complicated sinusitis. *Headache* 2006;46:517-20.
- 19 Davenport R. Acute headache in the emergency department. *J Neurol Neurosurg Psychiatry* 2002;72:ii33-ii7.
- 20 Arnold M, Cumurciuc R, Stapf C, Favrole P, Berthet K, Bousser MG. Pain as the only symptom of cervical artery dissection. *J Neurol Neurosurg Psychiatry* 2006;77:1021-4.
- 21 De Bruijn SF, Stam J, Kappelle LJ. Thunderclap headache as first symptom of cerebral venous sinus thrombosis. CVST Study Group. *Lancet* 1996;348:1623-5.
- 22 Cumurciuc R, Crassard I, Sarov M, Valade D, Bousser MG. Headache as the only neurological sign of cerebral venous thrombosis: a series of 17 cases. *J Neurol Neurosurg Psychiatry* 2005;76:1084-7.
- 23 Timoteo A, Inacio N, Machado S, Pinto AA, Parreira E. Headache as the sole presentation of cerebral venous thrombosis: a prospective study. *J Headache Pain* 2012;13:487-90.
- 24 Bartynski WS, Boardman JF. Catheter angiography, MR angiography, and MR perfusion in posterior reversible encephalopathy syndrome. *AJNR Am J Neuroradiol* 2008;29:447-55.
- 25 Schievink WI, Wijdevicks EF, Meyer FB, Sonntag VK. Spontaneous intracranial hypotension mimicking aneurysmal subarachnoid hemorrhage. *Neurosurgery* 2001;48:513-6; discussion 6-7.
- 26 Dodick DW, Wijdevicks EF. Pituitary apoplexy presenting as a thunderclap headache. *Neurology* 1998;50:1510-1.
- 27 Schievink WI, Thompson RC, Loh CT, Maya MM. Spontaneous retroclival hematoma presenting as a thunderclap headache. Case report. *J Neurosurg* 2001;95:522-4.
- 28 Broner S, Lay C, Newman L, Swerdlow M. Thunderclap headache as the presenting symptom of myocardial infarction. *Headache* 2007;47:724-5.
- 29 Mistry N, Mathew L, Parry A. Thunderclap headache. *Pract Neurol* 2009;9:294-7.
- 30 Savitz SI, Edlow J. Thunderclap headache with normal CT and lumbar puncture: further investigations are unnecessary. For. *Stroke* 2008;39:1392-3.
- 31 Moussouttas M, Mayer SA. Thunderclap headache with normal CT and lumbar puncture: further investigations are unnecessary. Against. *Stroke* 2008;39:1394-5.
- 32 O'Neill J, McLaggan S, Gibson R. Acute headache and subarachnoid haemorrhage: a retrospective review of CT and lumbar puncture findings. *Scot Med J* 2005;50:151-3.
- 33 Ohkuma H, Tsurutani H, Suzuki S. Incidence and significance of early aneurysmal rebleeding before neurosurgical or neurological management. *Stroke* 2001;32:1176-80.

Cite this as: *BMJ* 2012;345:e8557

© BMJ Publishing Group Ltd 2012

Box 5 Criteria for cluster headache⁶

In patients with daily attacks of strictly unilateral severe headaches and normal test results, assess for cluster headache using the following criteria:

- A At least five attacks fulfilling criteria B through to D
- B Severe or very severe unilateral orbital, supraorbital, or temporal pain lasting 15-180 minutes if untreated
- C Headache is accompanied by at least one of the following:
 - Ipsilateral conjunctival injection or lacrimation (or both)
 - Ipsilateral nasal congestion or rhinorrhoea (or both)
 - Forehead and facial sweating
 - Ipsilateral eyelid edema
 - Ipsilateral forehead and facial sweating
 - Ipsilateral miosis or ptosis (or both)
 - A sense of restlessness or agitation
- D Attacks have a frequency from one every other day to eight per day
- E Not attributed to another disorder (investigations are normal)

Tips for non-specialists

Careful history taking is needed to identify a thunderclap headache because patients seldom mention how long their headache took to peak

Obtain the time to peak and the precise intensity of the maximal pain on an 11 point scale (0 no pain; 1-3 mild pain; 4-6 moderate pain; 7-9 severe pain; 10 worst pain ever)

Always refer a patient with thunderclap headache to the emergency department as soon as possible

First line investigations always include plain brain computed tomography (CT) followed by a lumbar puncture if the tomogram is normal

Patients with isolated thunderclap headache and normal physical examination, normal brain CT, and normal cerebrospinal fluid results can still have a serious underlying condition; refer to a multidisciplinary neurology team

Questions for future research

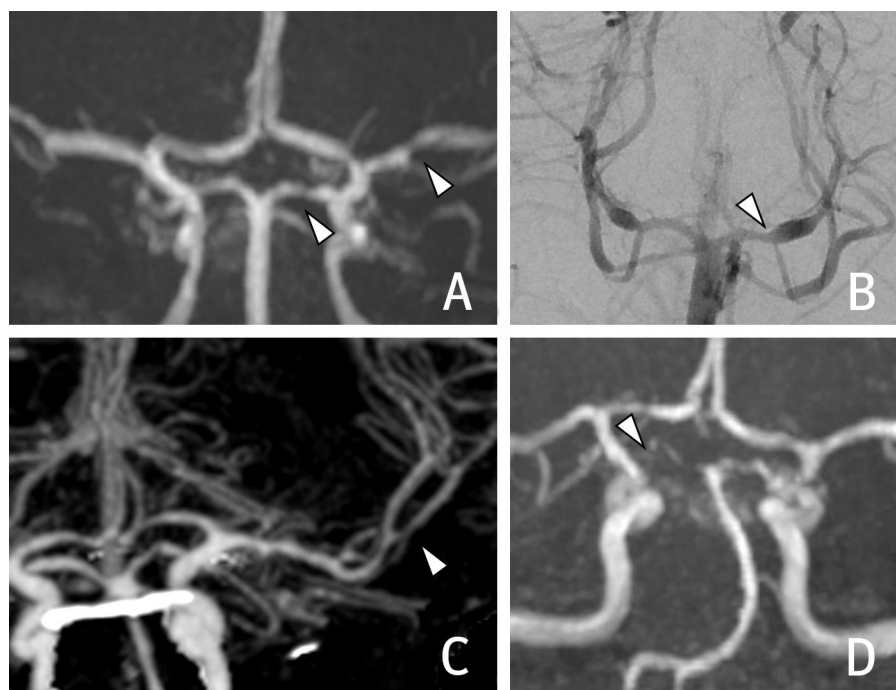
In cases of isolated thunderclap headache, what is the incidence of the various underlying disorders, especially reversible cerebral vasoconstriction syndrome, cervical artery dissection, and cerebral venous thrombosis?

In cases of thunderclap headache with normal computed tomography (CT) and cerebrospinal fluid results, what is the diagnostic yield of cervical and cerebral CT angiography, magnetic resonance angiography, and magnetic resonance imaging?

What are the mechanisms underlying the explosive onset of pain in thunderclap headache according to the various underlying causes?

What biomarkers could be used as diagnostic screening tools?

Figure



Cerebral angiography in cases with reversible cerebral vasoconstriction syndrome (RCVS). (A and D) Cerebral magnetic resonance angiography in two patients showing segmental constrictions (arrowheads); in (D) the right posterior cerebral artery is severely constricted. (B) Conventional catheter cerebral angiography in RCVS, showing segmental dilation of both posterior cerebral arteries (arrowhead). (C) Cerebral computed tomography angiography in RCVS showing a short stenosis of a branch of the left middle cerebral artery (arrowhead)